

Treatment of the gravity dependence of downbeat nystagmus with 3,4-diaminopyridine

Abstract—The authors examined the effect of 3,4-diaminopyridine (DAP) on the gravity-dependent (GD) vertical ocular drift component of downbeat nystagmus in 11 patients with idiopathic cerebellar ataxia. With the head tilted downward (45°), DAP reduced slow phase velocity (SPV) in 7 of 11 patients by 36%. Its efficacy correlated with the GD modulation. DAP minimizes the gravity-independent velocity bias and may improve deficient inhibitory cerebellar control on overacting otolith–ocular reflexes.

NEUROLOGY 2006;67:905–907

A. Sprenger; H. Rambold, MD; T. Sander; S. Marti, MD; K. Weber, MD; D. Straumann, MD; and C. Helmchen, MD

Downbeat nystagmus (DBN) is a frequent ocular motor sign in patients with midline cerebellar lesions. Failure of the vertical velocity-to-position integration explains the increase of upward drift velocity with downward gaze and the decrease with upward gaze.¹ Vertical drift in DBN is composed of a gravity-independent (GI) drift component already present with gaze straight ahead and gravity-dependent (GD) component, which is maximal in prone and minimal in supine position and probably mediated by otolith–ocular reflexes (OORs).^{2,3} Hence, DBN is most disabling for many patients in a head forward bending position in everyday life, for example, kitchen or desk work.

Recently, the potassium channel blocker 3,4-diaminopyridine (DAP) has been shown effective in reducing DBN in some but not all patients with their heads upright.⁴ It remained undetermined how DAP affects the GD component of DBN. We have shown in a single patient that DAP may be particularly efficient in reducing DBN in the head bending forward position and in the prone body position.² It has been suspected that DAP exerts its influence more on the GD drift component and less on the GI drift component.⁵ To corroborate this hypothesis, we examined the effect of DAP on the GD modulation of vertical drift in DBN in 11 patients with idiopathic cerebellar ataxia and DBN. A change of the head position-dependent modulation of DBN in the absence of any

effect on DBN in the head-erect position would probably indicate a distinct influence of DAP on the OOR.

Methods. Eleven patients with idiopathic DBN (7 women, 4 men; ages 36 to 83) were prospectively included (see table E-1 on the *Neurology* Web site; go to www.neurology.org). Cranial MRI did not reveal focal lesions in the cerebellum or brainstem. Neurologic examination in upright position demonstrated typical DBN. In six patients, DBN clinically increased in a forward head bending position. All patients gave informed written consent. The protocol was approved by the local ethics committee.

Eye movements were recorded by video-based eye-tracking systems.^{2,3} Visual targets were presented in gaze straight ahead and $\pm 10^\circ$ vertically and $\pm 20^\circ$ horizontally. Five pitch positions of the head relative to the upright position were examined (each 15 seconds): head upright (0°), bending forward by 45° (–45°) and 90° (–90°, nose down), bending backward by 45° (45°) and 90° (90°). Eye movement recordings were performed both prior to and 45 minutes after 20-mg DAP ingestion.

Mean SPV for each period was calculated with its SE from the median velocity of the nystagmus that occurred (200-millisecond period) for each head and eye position. The amount of head position dependence of ocular drift was calculated from the difference between the lowest and highest SPV of the different head positions (gravity-modulation index). Statistical differences were significant at $p < 0.05$ (analysis of variance and Student *t* test). Data are presented as means \pm SEM.

Results. The SPV of DBN was taken to assess efficacy of DAP treatment. Prior to DAP ingestion, the mean SPV of DBN was $10.2 \pm 2.4^\circ/\text{s}$ with lateral gaze while the head was erect. On 45° downward head tilt, DBN increased to $14.3 \pm 3.6^\circ/\text{s}$; i.e., by 40%. The gravity-modulation index ranged from 2.2 to 41.4°/s. With the head erect, DAP reduced SPV with lateral gaze by $2.0 \pm 1.2^\circ/\text{s}$ (= 24%). At 45° downward head tilt, SPV was reduced by $4.0 \pm 1.1^\circ/\text{s}$ (=28%). Response to DAP varied considerably between subjects (figure 1), but 7 of 11 patients improved by more than 25% in the head bended forward position (–45°), on average by 36% (gravity-modulation index of 15.9°/s). Figure 2 shows the head position (gravity) dependence of ocular drift in five different pitch positions for three patients. The reduction of SPV was either asymmetric (figure 2A) or symmetric (figure 2B, parallel shift). In contrast, three patients had only a small or no GD component with gaze straight ahead (figure 2C) or with lateral gaze (figure 2D); in them, DAP efficacy was low. In all patients, the GD modulation of SPV was correlated with the efficacy of DAP ($r = 0.753$, $p < 0.01$) (figure 3). Interestingly, the relation of the GD modulation to the vertical velocity bias in the head-erect position before and after DAP ingestion showed in some patients an effect exclusively on the GD component (figure E-1).

Additional material related to this article can be found on the *Neurology* Web site. Go to www.neurology.org and scroll down the Table of Contents for the September 12 issue to find the title link for this article.

From the Department of Neurology (H.R., T.S., C.H.), University of Lübeck, Germany; and Department of Neurology (S.M., K.W., D.S.), University of Zürich, Switzerland.

Disclosure: The authors report no conflicts of interest.

Received March 8, 2006. Accepted in final form May 4, 2006.

Address correspondence and reprint requests to Dr. C. Helmchen, Department of Neurology, University Lübeck, Ratzeburger Allee 160, D-23538 Lübeck, Germany; e-mail: Christoph.Helmchen@neuro.uni-luebeck.de

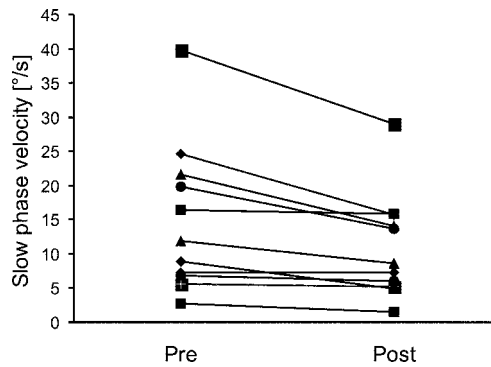


Figure 1. Mean slow phase velocity ($^{\circ}/s$) of downbeat nystagmus with lateral gaze (40°) in the head bended forward position (45°) before and after 3,4-diaminopyridine ingestion.

Discussion. This study provides evidence that DAP exerts two distinct effects on vertical ocular drift in patients with cerebellar DBN: First, DAP minimizes the vertical velocity bias.⁴ Second, we show that DAP reduces GD modulation of DBN in a way largely independent of the vertical velocity bias. The GD component of DBN has been proposed to reflect disinhibition of a physiologically overactive OOR due to cerebellar disease,³ which is thought to be controlled by the flocculus⁶ and nodulus.⁷

DAP reduced SPV of DBN in the head-erect position, but even more when the head was tilted forward. The spectrum of therapeutic responses was broad, which explains why the mean effect was moderate and raises questions as to what determines the therapeutic efficacy of DAP. Interestingly, some patients hardly responded in the head-erect position (figure 2A) but showed a strong suppression of DBN when the head was bended forward. This finding might indicate a particular, but asymmetric, influence on the GD component with only minor or no effects on the vertical velocity bias (see additional data on the Web site). In contrast, a parallel shift of the curve reflects attenuation of the vertical velocity bias largely independent of the GD component.

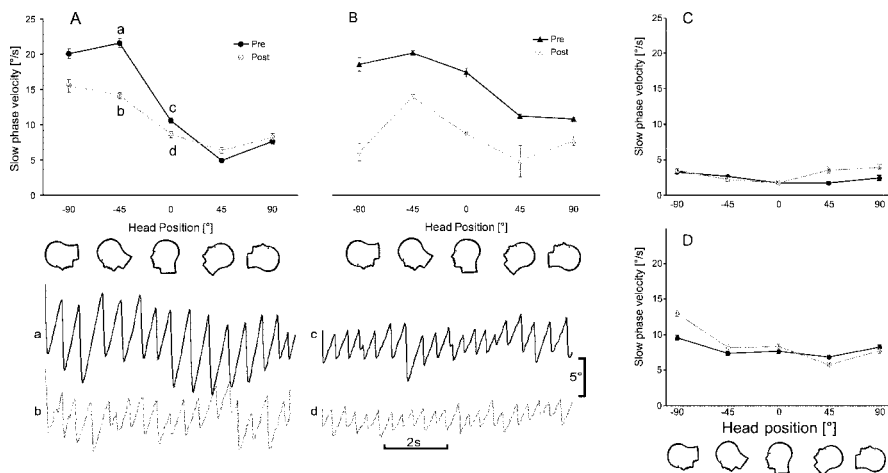


Figure 2. Vertical ocular drift velocity (slow phase velocity [SPV] \pm SE) in lateral gaze for two patients in different head positions (abscissa) before (black) and after (gray trace) 3,4-diaminopyridine (DAP) ingestion. (Below) Original recordings before (a, c, black) and after DAP (b, d, gray). Patients exhibit a gravity-dependent modulation of SPV with an asymmetric (A) or symmetric (B) reduction of SPV for all head positions (parallel shift). Corresponding traces are shown on the right side for a patient without response to DAP with gaze straight ahead (C) and lateral gaze (D).

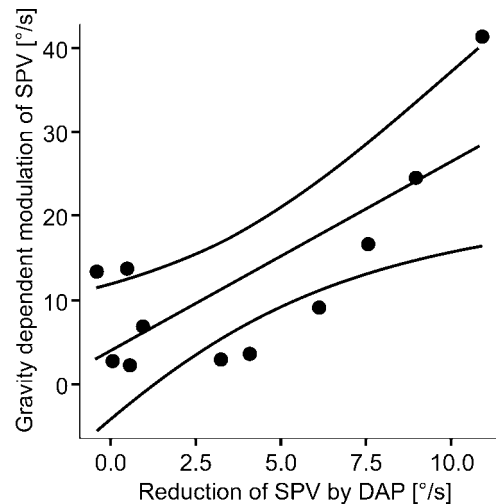


Figure 3. Gravity-dependent modulation of slow phase velocity is shown as a function of the efficacy of 3,4-diaminopyridine (in the head bended forward position, 45°).

The GD modulation of SPV was correlated with the efficacy of DAP: The larger the SPV of DBN and the larger the GD modulation, the better DAP suppressed DBN. This is of clinical importance as many activities of daily living are performed with the head bending forward (e.g., working in the kitchen, at the desk or computer) and the modulation of DBN dependent on body- and head-position can easily be assessed on clinical examination. Moreover, five of our patients noticed clinical improvement after DAP ingestion.

The reported effect is likely to be mediated by an improvement of the physiologic cerebellar inhibition of the overactive OOR.³ Patients should be asked for head positional effects on vertical oscillopsia. A strong modulation of DBN with head-positioning maneuvers in the pitch plane should encourage a therapeutic trial with DAP as they are likely to benefit. As our data demonstrate, the DAP effect on the OOR may be independent of the velocity bias of DBN and may even occur in the absence of DBN.

References

1. Robinson DA, Zee DS, Hain TC, Holmes A, Rosenberg LF. Alexander's law: its behavior and origin in the human vestibulo-ocular reflex. *Ann Neurol* 1984;16:714-722.
2. Helmchen C, Sprenger A, Rambold H, Sander T, Kompf D, Straumann D. Effect of 3,4-diaminopyridine on the gravity dependence of ocular drift in downbeat nystagmus. *Neurology* 2004;63:752-753.
3. Marti S, Palla A, Straumann D. Gravity dependence of ocular drift in patients with cerebellar downbeat nystagmus. *Ann Neurol* 2002;52:712-721.
4. Strupp M, Schuler O, Krafczyk S, et al. Treatment of downbeat nystagmus with 3,4-diaminopyridine: a placebo-controlled study. *Neurology* 2003;61:165-170.
5. Halmagyi GM, Leigh RJ. Upbeat about downbeat nystagmus. *Neurology* 2004;63:606-607.
6. Snyder LH, King WM. Behavior and physiology of the macaque vestibulo-ocular reflex response to sudden off-axis rotation: computing eye translation. *Brain Res Bull* 1996;40 (5-6):293-302.
7. Precht W, Volkind R, Maeda M, Giretti ML. The effects of stimulating the cerebellar nodulus in the cat on the responses of vestibular neurons. *Neuroscience* 1976;1:301-312.

NeuroImages

Transient paraparesis due to right carotid stenosis with left anterior cerebral artery aplasia

Arun N. Babu, MD; Lakshmi A. Babu, MD;
Mark Raden, MD; and Kavita Ahuja, DO, Brooklyn and Staten Island, NY

A 76-year-old man with hypertension and hypercholesterolemia presented with multiple episodes, over 5 days, of numbness and weakness of both lower extremities or just the right lower extremity. Each episode lasted about 30 seconds and usually occurred on standing. Cerebral angiography revealed a critical right internal carotid artery stenosis (figure). Both anterior cerebral arteries were supplied from the stenotic right carotid system, resulting in the bilateral symptoms of transient paraparesis. Symptoms resolved after carotid surgery. Aplasia of a proximal ACA occurs in up to 7% of people.¹ Carotid stenosis should be considered in the differential diagnosis of transient paraparesis.²

Copyright © 2006 by AAN Enterprises, Inc.

1. Riggs HE, Rupp C. Variation in form of circle of Willis. *Arch Neurol* 1963;8:8-14.
2. Ho RTK, Harrison MJG, Earl CJ. Transient paraparesis—a manifestation of ischaemic episodes in the anterior cerebral artery territory. *J Neurol Neurosurg Psychiatry* 1986;49:101-102.

The authors thank David Hirschorn, MD, for assistance with the image.

Disclosure: The authors report no conflicts of interest.

Address correspondence and reprint requests to Dr. Arun N. Babu, 27 New Dorp Lane, Staten Island, NY 10306.

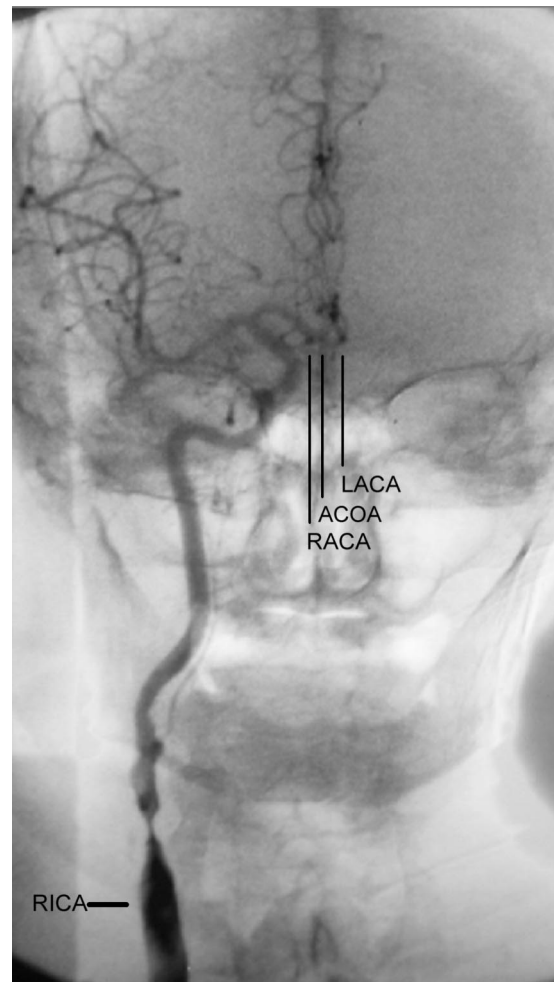


Figure. There was a critical right internal carotid artery (RICA) stenosis. The proximal A1 segment of the left anterior cerebral artery (LACA) was aplastic. As a result, the left ACA originated via the anterior communicating artery (ACO) from the right ACA (RACA). There were no other significant stenoses.