

Vestibulo-Ocular Responses During Static Head Roll and Three-Dimensional Head Impulses After Vestibular Neuritis

A. SCHMID-PRISCOVEANU¹, D. STRAUMANN¹, A. BÖHMER^{2,*} and H. OBZINA¹

From the Departments of ¹Neurology and ²Otorhinolaryngology, Zurich University Hospital, Zurich, Switzerland

Schmid-Priscoveanu A, Straumann D, Böhrer A, Obzina H. Vestibulo-ocular responses during static head roll and three-dimensional head impulses after vestibular neuritis. Acta Otolaryngol (Stockh) 1999; 119: 750–757.

This study aimed to investigate whether unilateral vestibular neuritis (VN) causes the same deficits of ocular counter-roll during static head roll (OCR_S) and dynamic vestibulo-ocular reflex gains during head impulses (VOR_{HI}) as unilateral vestibular deafferentation (VD). Ten patients with acute and 14 patients with chronic vestibular paralysis after VN were examined. The testing battery included fundus photography of both eyes with the head upright (binocular cyclorotation) and dual search coil recordings in a three-field magnetic frame. With one dual search coil on the right eye and the other on the forehead, the following stimuli were given: *i*) Halmagyi-Curthoys head impulses about the vertical, horizontal and torsional axes. *ii*) Static roll positions of the head up to 20° right- and left-ear-down by movement of the neck. The comparison group consisted of 19 healthy subjects. Compared with the VD-patients, as reported in the literature, acute VN-patients showed the same pattern of OCR_S gain reduction and binocular cyclorotation (CR_b). The main feature that distinguished chronic VN-patients from chronic VD-patients was the normalization of the torsional VOR_{HI} gain to the affected side, whereas the VOR_{HI} gains in the horizontal and vertical directions did not show recovery (as in the patients with chronic VD). Chronic VN-patients differed from acute VN-patients by: *i*) symmetrical OCR_S gains, *ii*) a less pronounced CR_b toward the affected side, and *iii*) a normal torsional VOR_{HI} gain toward the affected side. Since the ipsilesional torsional VOR_{HI} gain did not recover in VD-patients, the normalization of this gain in our VN-patients can only be explained by a (partial) recovery of otolith function on the side of the lesion after the neuritis. *Key words:* counter-roll, oculomotor, otoliths, semicircular canals, vestibulo-ocular reflex.

INTRODUCTION

Ocular counter-rolling during static head roll (OCR_S) results from a otolith-ocular reflex activated by the gravitational force acting on the otolith organs. The ocular motor response of this static reflex consists of a small, torsional conjugate eye movement opposite to the direction of the static head roll. In normal subjects, only 10–20% of the static head roll is compensated by the counter-rotation of the eyes; this response is roughly symmetrical (1, 2). The gains of OCR_S have also been studied in patients with long-standing vestibular deafferentation. These measurements, however, were not consistent: the gain of OCR_S was either reduced during head roll to the side of the lesion (3) or during head roll to the other side (4, 5). In patients who were tested shortly after unilateral deafferentation, a marked ipsilateral reduction of the OCR_S gain was observed; this low gain tended to normalize after several years (6).

In 1988, Halmagyi & Curthoys described the “head-impulse test” that allows to reliably identify the side of a peripheral vestibular lesion at the bedside (7). In this test, a thrust is applied to the patient’s head; if the head is rotated to the side of the lesion, the eyes can not be stabilized in space by the vestibulo-ocular reflex (VOR). Using three-dimensional search coil recordings (dual search coils on the

eyes and the head), the high-frequency (peak accelerations of the head up to 10000°/s²) performance of the VOR (VOR_{HI}) can be quantitatively assessed in the planes of individual semicircular canals (8). Patients with unilateral vestibular deafferentation showed permanently reduced gains of VOR_{HI} during horizontal and torsional head impulses to the side of the lesion and during vertical (upward and downward) head impulses (9).

Vestibular neuritis is a sudden unilateral deficit of vestibular function without auditory symptoms in otherwise healthy persons. Although the exact cause cannot be demonstrated in most patients with vestibular neuritis, a viral etiology is likely (10). Since vestibular neuritis seems to affect the eighth nerve only incompletely (11), we asked whether patients after vestibular neuritis (VN) show a different pattern of gain reduction during static (OCR_S) and dynamic (VOR_{HI}) vestibular stimulation as patients after vestibular deafferentation/labyrinthectomy (VD). Hence, in this investigation of patients with acute or chronic vestibular paralysis after VN, our specific questions were:

1. In acute VN-patients, is the gain of static ocular counter-roll reduced during head roll to the side of the lesion (as in acute VD-patients)?
2. In chronic VN-patients, do the gains of static ocular counter-roll tend to become normal (as in chronic VD-patients)?

* Deceased October 21, 1998.

3. In acute VN-patients, are there consistent gain reductions during horizontal and torsional head impulses to the side of the lesion and during vertical head impulses (as in VD-patients)?
4. In chronic VN-patients, are the gain reductions during head impulses in specific directions still present (as in VD-patients)?

Using the three-dimensional search coil technique we recorded eye-in-head movements in patients with acute and chronic unilateral vestibular paralysis during static head roll and head impulses. Results were compared with a comparison group of normal subjects. The main result was that, in contrast to the patients with VD (as reported in the literature), not only OCR_S gains, but also torsional VOR_{HT} gains normalized in the chronic state of VN.

MATERIAL AND METHODS

Subjects

The patients included in this study were initially diagnosed by calorics, electronystagmography and/or dual search coil recordings of the three-dimensional head impulse test. In all patients with vestibular paralysis after vestibular neuritis, the head impulse test was pathological when the head was rotated toward the side of the lesion. The patients were partitioned into two groups:

Acute group: Ten patients (A1–10) with unilateral vestibular paralysis 1 day to 2 weeks after vestibular neuritis (6 males, 4 females; age range 26–77 years).

Chronic group: A total of 14 patients (C1–14) with unilateral vestibular paralysis 6 months to 6 years after vestibular neuritis (9 males, 5 females; age range 30–84 years).

Three patients, were included in both the chronic and acute group since they could be tested at two different time intervals after the onset of the vestibular neuritis.

The comparison group consisted of 19 healthy subjects (8 males, 11 females; age range 22–57 years).

The informed consent of patients and control subjects was obtained after full explanation of the experimental procedure.

Three-dimensional search coil recordings

Eye and head movements were recorded in a three-field magnetic frame (Rommel type system, modified by A. Lasker, Baltimore, USA) (12) using dual scleral search coils (Skalar Instruments, Delft, Netherlands) (1, 13, 14). One dual search coil was placed on the right eye around the cornea (after anaesthetizing the conjunctiva with Oxybuprocaine 0.4%),

the other was tightly fixed on the forehead with adhesive tape. Since the magnetic frame was earth-stationary, recorded movements of eye and head in the frame could directly be referenced to space (eye-in-space, head-in-space). Digitized data were sampled with 1,000 Hz and stored on the hard disk of a computer.

From the raw signals and the calibration values, rotation vectors were computed. These vectors describe three-dimensional eye or head positions as single rotations from a reference position (15). Rotation vectors of eye-in-space (g) and head-in-space (h) were further processed on a PC using interactive programs written in MATLAB[®] Version 5.2. Eye-in-head rotation vectors (e) were computed using the formula:

$$e = (-h + g - h \times g)/(1 + h \times g)$$

where \times denotes the vector cross-product.

From eye-in-head rotation vectors (e) and their derivative (de), we computed angular eye-in-head velocity vectors (ω) applying the formula:

$$\omega = 2(de + e \times de)/(1 + |e|^2)$$

Angular eye velocity vectors are oriented parallel to the instantaneous ocular rotation axis; their lengths denote the velocity of rotation in rad/s. An analogous formula was used to compute head-in-space angular velocity vectors. For convenience, movements were plotted according to the clinician's definition of directions: rightward, upward, and clockwise rotations of the eye or head (as seen by the subject) were positive.

During experiments, subjects were seated inside the magnetic frame (side length: 1.4 m). Care was taken to position the centre of the interpupillary line in the centre of the magnetic frame. The head was restrained with a bite bar that could be moved about a torsional axis to produce defined roll positions of the head. The amount of static head roll could be read from an inclinometer fixed to the bite bar. While the subject was fixing a light dot 1.24 m straight ahead, his head was slowly tilted up to 20° in the left- or right-ear-down direction by the investigator. This position was maintained for at least 5 s.

After removing the bite bar, horizontal, vertical, and torsional head impulses (amplitude: 15–25°; duration: 150–200 ms; peak velocity: $\sim 250^\circ/s$; peak acceleration $\sim 10,000^\circ/s^2$) were applied by the investigator standing behind the subject. The direction of the impulses was pseudo-randomly intermingled; five head rotations were applied to each side. Subjects were instructed to always fix the light dot straight ahead.

Fundus photography

After dilation of both pupils, fundus photographs were obtained with the head maintained in an erect position by use of a chin rest. The amount of cyclorotation was determined by measuring the angle between the earth-horizontal border of the picture and the line connecting the centres of the papilla and the fovea. For each eye, we took the median cyclorotation on 3–4 photographs. Fundus photography was performed in 13 of 14 chronic and 8 of 10 acute patients.

Electronystagmography

Movements of the left eye were recorded using direct current electro-oculography (EOG) (One patient from the chronic group could not be tested on the turntable because of claustrophobia). The patients were seated on a vestibular chair, which was surrounded by an optokinetic drum. Vestibular stimuli to both sides were applied in total darkness and consisted of velocity steps (end velocity: $100^\circ/\text{s}$; peak acceleration: $100^\circ/\text{s}^2$).

Side of the vestibular lesion

In the acute group, five patients had a paralysis on the right and five on the left side. Among the 14 patients with chronic vestibular paralysis, 9 patients were affected on the right, 5 on the left side. For convenience, all left-sided lesions were mirrored to the right side, thus in these patients, data obtained from vestibular stimulations in the horizontal and torsional, but not vertical, planes were multiplied by (-1) .

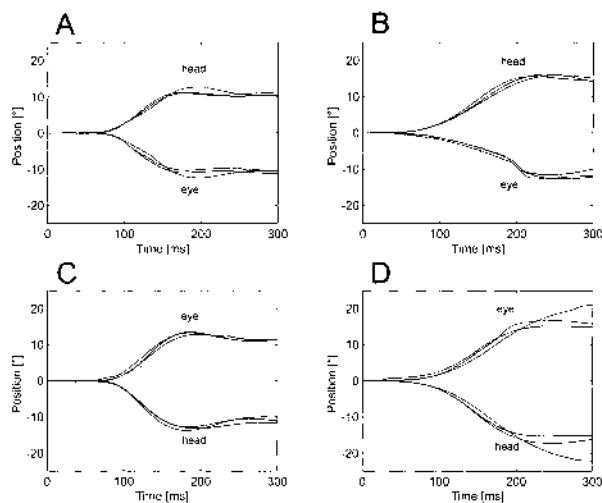


Fig. 1. Examples of horizontal head-impulses in a healthy subject (panels A and C) and a patient with a right-sided acute vestibular hypofunction (panels B and D).

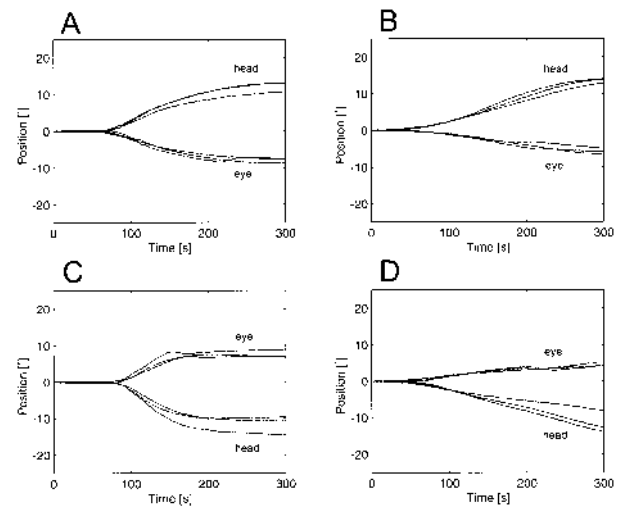


Fig. 2. Examples of torsional head impulses in the same subjects as in Fig. 1 (healthy subject: panels A and C; patient: panels B and D).

RESULTS

Figure 1 shows typical examples of head impulses in the horizontal plane. The left panels (Fig. 1A,C) depict data from a healthy subject, the right panels (Fig. 1B,D) from a patient (A4) with an acute right-sided vestibular neuritis (VN). The traces on the upper panels (Figs 1A,B) represent head-in-space (“head”) and eye-in-head (“eye”) movements during three head impulses to the right, on the lower panels (Figs 1C,D) the corresponding movements elicited by head impulses to the left are shown.

The following definition of the vestibulo-ocular gain during head impulses (VOR_{HI}) was adopted: At peak head velocity, we determined the position change of both head-in-space (Δh) and eye-in-head (Δe) from the beginning of the impulse. The gain (g) was computed by the following formula:

$$g = \Delta e / \Delta h$$

The dotted lines in Figure 1 mark the moment in time when peak head velocity was reached (median value of the three trials). For each set of head impulses in one direction, the average gain, G , was computed (G_R , G_L , G_U , G_D , G_{CW} , G_{CCW} : respective average gains during rightward, leftward, upward, downward, clockwise and counterclockwise rotations of the head, as seen by the subject). The healthy subject (Figs 1A,C) showed normal gains to both sides (G_R : 0.95; G_L : 0.81) while in the patient (Figs 1B–D), G_R was clearly decreased (G_R : 0.5; G_L : 0.85). Notice the correcting saccade in Figure 1B, by which the patient compensated the decreased gain of the VOR_{HI} to refix the light straight ahead.

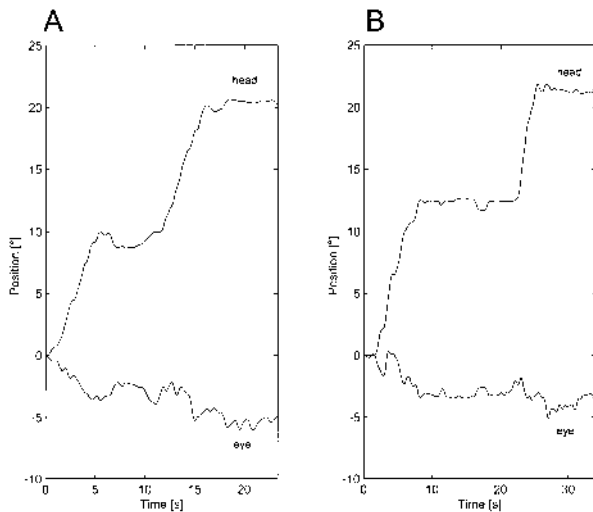


Fig. 3. Examples of ocular counter-roll during static head roll (OCR_S) in the right-ear-down-position. Same subjects as in Figure 1. OCR_S gain in the healthy subject (panel A): 0.2; in the patient (panel B): 0.11.

Figure 2 is given in the same format as the previous figure, but here movements of head-in-space and eye-in-head during roll (= torsional) head impulses are plotted. The torsional VOR_{HI} gains in the healthy subject during clockwise (Fig. 2A) and counterclockwise (Fig. 2C) head impulses were symmetric and rather high (G_{CW} : 0.78; G_{CCW} : 0.76). In the patient (A4), however, there was a gain asymmetry with the lower values for ipsilesional torsional head impulses (G_{CW} : 0.48; G_{CCW} : 0.60).

On Figure 3, examples of ocular counter-roll during static head roll (OCR_S) to the right side are shown for the same two subjects as in the previous two figures. The head roll was applied in two steps to help the patient relax his neck muscles. The OCR_S

gain was computed at a head roll position of 20°.

Using an interactive computer program, an interval of about 2–5 s, during which fluctuations of head-in-space and eye-in-head positions were minimal, was marked, and the corresponding median positions were calculated to determine the OCR_S gain. Clearly, in the healthy subject the OCR_S gain was higher (Fig. 3A) than in the patient (Fig. 3B).

On each subject, we performed two trials of head roll: in the first trial, the head was slowly moved from the upright to the right-ear-down, and then to the left-ear-down position; in the second trial, the head was first moved from the upright to the left-ear-down, and then to the right-ear-down position. The two gains obtained for each 20° roll position were averaged (G_{RED} , G_{LED} : average OCR_S gains during right- and left-ear-down head positions, respectively).

On Figure 4, the OCR_S gains during static right- (G_{RED}) and left-ear-down (G_{LED}) head roll are plotted against each other for the three groups tested (“normal”, “acute”, “chronic”). Data points that lie on the diagonal line indicate symmetric OCR_S gains. The dotted lines mark the range of normal values, which, in our definition, is always limited by the second lowest and second highest value of the normal group. Individual asymmetries between right- and left-ear-down OCR_S gains, as visualized by the scatter of data points around the diagonal line, were present not only in the acute and chronic, but also in the normal group. 90% of the acute patients (central panel) lie below the central quadrant, as the OCR_S gains for head roll to the affected side (= right side) were reduced in 60% and in 20% during head roll to both sides. Only one patient in the acute group showed decreased OCR_S during head roll to the normal side. In the chronic group (right panel), 50%

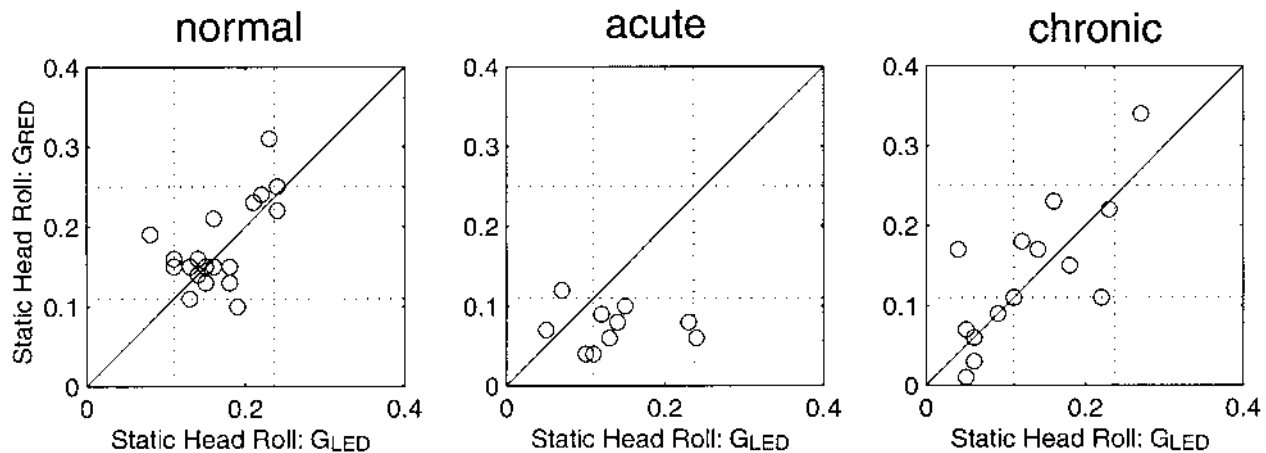


Fig. 4. Gains of static ocular counter-roll (OCR_S) during right- (G_{RED}) and left-ear-down (G_{LED}) head roll positions are plotted against each other in the three groups (“normal”, “acute” and “chronic”) tested. Dotted lines: range of OCR_S gains in the healthy subjects. Diagonal line: symmetry of OCR_S .

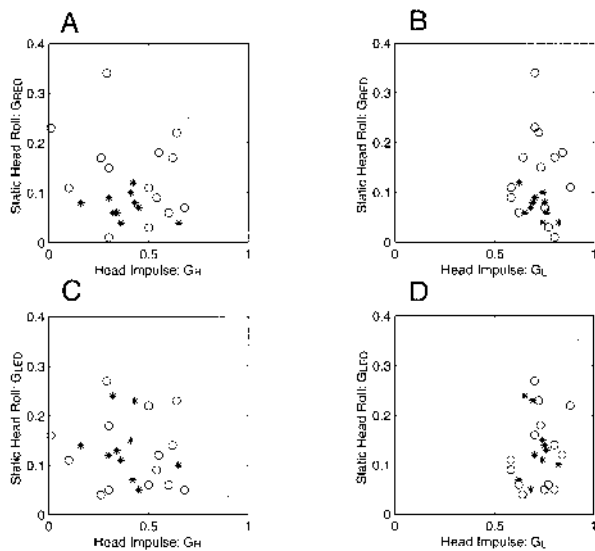


Fig. 5. Gains of static ocular counter-roll (OCR_S) in response to right- (G_{RED}) and left-ear-down (G_{LED}) static head roll positions versus vestibulo-ocular gains during head impulses (VOR_{HI}) in the horizontal plane (gain during rightward impulse: G_R ; during leftward impulse: G_L).

Dotted lines: range of OCR_S and VOR_{HI} gains in the healthy subjects.

Asterisks: acute patients. *Circles:* chronic patients.

showed normal OCR_S gains in both directions (central quadrant), and in 36% OCR_S gains to both sides were decreased (lower-left quadrant). Only 1 patient showed a unilaterally decreased OCR_S gain, but during head roll to the unaffected side. One patient showed an abnormally high OCR_S gain to both sides.

Figures 5–7 summarize the vestibulo-ocular gains during static head roll and head impulses. The values measured in the patients with acute (asterisks) and chronic (circles) vestibular paralysis were compared to the group of healthy subjects. The latter group is represented by dotted lines that mark the range of normal gains of OCR_S (ordinate) and VOR_{HI} (abscissa). As already stated, these lines mark the second lowest and second highest values and divide each panel into different sectors, which help to visualize possible data clustering.

The four panels of Figure 5 compare static ocular counter-roll gains (G_{RED} , G_{LED}) with dynamic horizontal VOR gains (G_R , G_L): On Figure 5A, OCR_S gains during head roll to the right (ipsilesional side) are plotted against the VOR_{HI} gains obtained during horizontal head impulses to the same side. (Recall that all data were mirrored, such that the vestibular lesion was on the right side.) The identical counter-roll data are shown in Figure 5B, but this time they are plotted against the horizontal VOR_{HI} gains during head impulses to the left side (= normal side). The lower two panels (Fig. 5C,D) depict the same

VOR_{HI} data on the abscissa as above, but now the OCR_S gains on the ordinates stem from recordings during head roll toward left-ear down.

All patients in the acute group (asterisks) showed a marked decrease in the horizontal VOR_{HI} gain to the lesioned side (Fig. 5A,C). A slight VOR_{HI} gain decrease during head impulses to the normal side was observed in 70% (Fig. 5B,D). In addition, 90% of the acute patients had a reduced OCR_S gain during head roll to the lesioned side (Fig. 5A,B). The OCR_S gain during head roll to the unaffected side was above the lower normal limit in 70% of the acute patients (Fig. 5C,D). No linear correlations between horizontal VOR_{HI} gains and OCR_S gains in different directions could be found (Fig. 5, all panels).

Similar to the patients in the acute group, all patients with chronic vestibular paralysis (circles) had a decreased horizontal VOR_{HI} gain during head impulses to the affected side (Fig. 5A,C). There was also a slight gain reduction during head impulses to the unaffected side in 57% of the chronic patients (Fig. 5B,D). Clearly, in the chronic group, there was no correlation between VOR_{HI} gains during horizontal head impulses and OCR_S gains.

Figure 6 corresponds to the previous figure, but plots OCR_S gains against VOR_{HI} gains during upward (Fig. 6A,C) and downward (Fig. 6B,D) head impulses. In the acute group, the VOR_{HI} gains were reduced in 30% during upward and in 80% during downward head impulses. Vertical VOR_{HI} gains of the acute patients overlapped with the corresponding gains of the chronic patients.

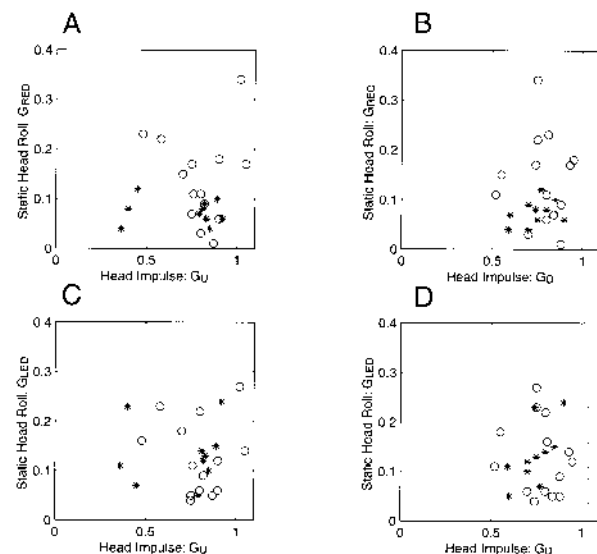


Fig. 6. OCR_S gains in response to right- (G_{RED}) and left-ear-down (G_{LED}) static head roll positions versus vestibulo-ocular gains during head impulses (VOR_{HI}) in the vertical plane (gain during upward impulse: G_U ; during downward impulse: G_D).

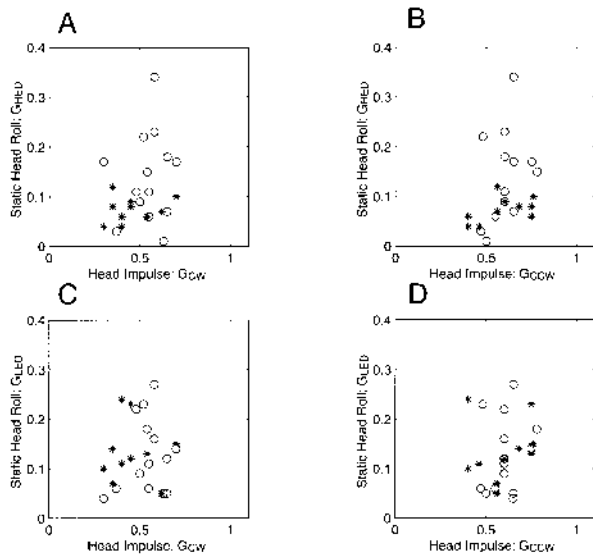


Fig. 7. OCR_S gains in response to right- (G_{RED}) and left-ear-down (G_{LED}) static head roll positions versus vestibulo-ocular gains during head impulses (VOR_{HI}) in the torsional plane (gain during clockwise impulse: G_{CW} ; during counterclockwise impulse: G_{CCW}).

In the chronic group, the VOR_{HI} gains during upward head impulses were reduced in 43%, and during downward head impulses in 71%. Again, no correlation was found between the VOR_{HI} gains during vertical head impulses and the OCR_S gains to either side.

Figure 7 corresponds to the two previous figures, but here VOR_{HI} gains during torsional head impulses are plotted against OCR_S gains. In the acute group, dynamic and static torsional vestibulo-ocular gains during ipsilesional head movements were reduced in 60% of the patients (Fig. 7A). Both OCR_S and VOR_{HI} gains during head roll to the unaffected side were reduced in only 30% of the acute patients (Fig. 7D).

In the chronic group, the majority of data points were within the normal gain limits of torsional head impulses to either side (ipsilesional torsional impulse: 86%; contralesional torsional impulse: 79%). Once more, no correlation between VOR_{HI} gains during torsional head impulses and OCR_S gains was found.

We then compared the OCR_S gains with the amount of binocular cyclorotation CR_b , as measured by fundus photography (Fig. 8). This parameter was defined by half the difference of excyclorotation of both eyes ($ExCR_{OD}$, $ExCR_{OS}$):

$$CR_b = (ExCR_{OD} - ExCR_{OS})/2$$

The ranges of CR_b and OCR_S in the normal group are again indicated by the dotted lines. In the acute group, 75% of the data points were outside of the

normal range, while in the chronic group, 62% of the patients were still inside the normal range of CR_b . Note that none of the patients showed a binocular cyclorotation toward the unaffected side. In both the chronic and the acute group, there was no significant correlation between the OCR_S gain and CR_b ($p > 0.05$).

On electro-oculographic testing on the turntable with a velocity step from 0 to $100^\circ/s$ (peak acceleration: $100^\circ/s^2$), all patients tested (acute and chronic group) showed an abnormally short time constant (< 10 s) of vestibular nystagmus.

DISCUSSION

Patients with acute (1 day to 2 weeks) and chronic (6 months to 6 years) vestibular paralysis after unilateral vestibular neuritis (VN) were tested with dual search coils. Gains of ocular counter-roll during static head roll (OCR_S) were compared with gains of dynamic vestibulo-ocular responses during head impulses (VOR_{HI}) in horizontal, vertical, and torsional directions. Only patients with a reduced horizontal VOR_{HI} gain to the side of the lesion were included in this study.

The majority of patients with acute VN had a reduced gain of OCR_S with the head rolled in the direction of the lesioned side. This suggests an otolith involvement in the acute phase of VN. As in the patients shortly after vestibular deafferentation (6), OCR_S gains were generally normal during head roll to the contralateral side, a pattern which can be expected if one applies Ewald's second law to the otolith organs (16). There was a marked binocular cyclorotation toward the affected side, as determined by fundus photography, which is in line with previous observations in patients after vestibular deafferentation (17, 18). By definition (inclusion criteria), the horizontal VOR_{HI} gain was reduced during head rotation toward the side of the lesion, but there was also a slight gain reduction of VOR_{HI} during head rotation toward the contralateral side, possibly as a

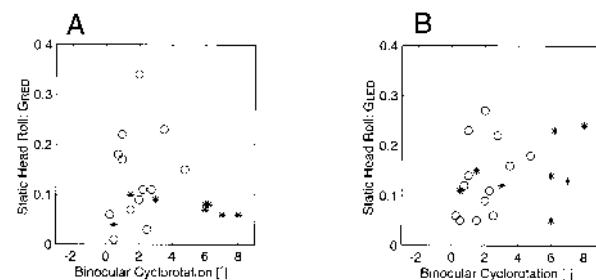


Fig. 8. Fundoscopic binocular cyclorotation of the eyes with the head upright (CR_b) versus OCR_S gains during right- (G_{RED}) and left-ear-down (G_{LED}) static head roll.

consequence of cerebellar inhibition of the vestibular nuclei in the context of adaptation (19). In the majority of acute patients, vertical VOR_{HI} gains were not only reduced during downward, but also during upward head impulses. However, there was a tendency of higher VOR_{HI} gains during upward head impulses, which could be expected if only the superior division of the vestibular nerve was affected, thus sparing afferences from the posterior semicircular canal (11). During torsional head impulses to the side of the lesion in the acute patients, VOR_{HI} gains were clearly reduced, but not during torsional head impulses to the other side.

The majority of patients with *chronic VN* showed symmetric OCR_S gains, which were either normal or reduced. Hence these gains did not indicate the side of the lesion, which agrees with data collected in patients after vestibular deafferentation (VD) (6). Explanations for the symmetrization of OCR_S gains in chronic VD-patients include central compensation mechanisms and upregulation of the cervico-ocular reflex (20). On average, fundusoscopic binocular cyclorotation toward the lesioned side was less pronounced in the chronic than in the acute group, which has also been reported in VD-patients (17). Horizontal VOR_{HI} gains were similar as in the acute group: in addition to the pronounced gain reduction during head impulses to the affected side, there was also a slight gain reduction during head impulses to the contralateral side. Vertical VOR_{HI} gains were reduced during both upward and downward head impulses, again similar to the acute patients. However, there was no significant torsional VOR_{HI} gain reduction to either side, which was in contrast to the acute group.

In summary, compared with the acute VD-patients, as reported in the literature, acute VN-patients showed the same pattern of horizontal VOR_{HI} gain deficits ((21)) as well as OCR_S gain reduction and binocular cyclorotation ((6)). In the literature, however, no data are available on torsional and vertical head impulse testing of patients shortly after vestibular deafferentation. Hence, a comparison of torsional VOR_{HI} between acute VN- and VD-patients could not be made. The main feature that distinguished chronic VN-patients from chronic VD-patients was the normalization of the torsional VOR_{HI} gain to the affected side, whereas the VOR_{HI} gains in the horizontal and vertical directions did not show a recovery, as in the patients with chronic VD.

The main parameters that separated chronic VN-patients from acute VN-patients were: *i*) symmetrical OCR_S gains, *ii*) a less pronounced binocular cyclorotation toward the affected side, and *iii*) a mostly normal torsional VOR_{HI} gain toward the affected

side. Since this ipsilesional torsional VOR_{HI} gain does not recover after vestibular deafferentation (9), the normalization of the torsional gain in the VN-patients cannot be explained by central compensation. It can also not be explained by a recovery of vertical semicircular canal afferents, since the reductions of vertical gains persisted in the chronic VN-patients. A logical explanation for this phenomenon could be that otolith function after VN (partly) recovered on the lesioned side. This improved otolith input could provide the necessary dynamic signals to drive the high-frequency torsional VOR during ipsilesional head roll and, hence, upregulate the ipsitonsional VOR_{HI} gain. In order to test this hypothesis it will be necessary to perform torsional VOR_I testing of patients after VN in both upright and supine positions.

ACKNOWLEDGMENTS

This work was supported by the Swiss National Science Foundation (3231-051938.97/3200-052187.97) and the "Betty and David Koetser Foundation for Brain Research".

REFERENCES

1. Collewijn H, van der Steen J, Ferman L, et al. Human ocular counterroll: assessment of static and dynamic properties from electromagnetic scleral coil recordings. *Exp Brain Res* 1985; 59: 185–96.
2. Nagel WA. Über kompensatorische Raddrehungen der Augen. *Z Physiol Psychol Sinnesorg* 1896; 12: 331–54.
3. Nelson JR, House WF. Ocular counter torsion as an indicator of otolith function: effects of unilateral vestibular lesions. *Trans Am Acad Ophthalmol Otolaryngol* 1971; 75: 1313–21.
4. Diamond SG, Markham CH. Ocular counterrolling as an indicator of vestibular otolith function. *Neurology* 1983; 33: 1460–9.
5. Gollas E. Untersuchung der Raddrehung der Augen bei einseitigem Labyrinthausfall. *Archiv für Ohren-, Nasen- und Kehlkopfheilkunde* 1936; 140: 340–54.
6. Takemori S, Tanaka M, Moriyama H. An analysis of ocular counter-rolling measured with search coils. *Acta Otolaryngol (Stockh)* ; Suppl 1989; 468: 271–6.
7. Halmagyi GM, Curthoys IS. A clinical sign of canal paresis. *Arch Neurol* 1988; 45: 737–9.
8. Aw ST, Haslwanter T, Halmagyi GM, et al. Three-dimensional vector analysis of the human vestibuloocular reflex in response to high-acceleration head rotations. I. Responses in normal subjects. *J Neurophys* 1996; 76: 4009–20.
9. Aw ST, Halmagyi GM, Haslwanter T, et al. Three-dimensional vector analysis of the human vestibuloocular reflex in response to high-acceleration head rotations. II. Responses in subjects with unilateral vestibular loss and selective semicircular canal occlusion. *J Neurophys* 1996; 76: 4021–30.

10. Schuknecht HF, Kitamura K. Vestibular neuritis. *Ann Otol Rhinol Laryngol* 1981; 90: 1–19.
11. Fetter M, Dichgans J. Vestibular neuritis spares the inferior division of the vestibular nerve. *Brain* 1996; 119: 755–63.
12. Rimmel RS. An inexpensive eye movement monitor using the scleral search coil technique. *IEEE Trans Biomed Eng* 1984; 4: 388–90.
13. Robinson DA. A method of measuring eye movement using a scleral search coil in a magnetic field. *IEEE Trans Biomed Electron* 1963; 10: 137–45.
14. Ferman L, Collewijn H, Jansen TC, et al. Human gaze stability in the horizontal, vertical and torsional direction during voluntary head movements, evaluated with a three-dimensional scleral induction coil technique. *Vision Res* 1987; 27: 811–28.
15. Haustein W. Considerations of Listing's law and the primary position by means of a matrix description of eye position control. *Biol Cybern* 1989; 60: 411–20.
16. Curthoys IS, Dai MJ, Halmagyi GM. Human otolith function before and after unilateral vestibular neurectomy. *J Vest Res* 1990/91; 1: 199–209.
17. Curthoys IS, Dai MJ, Halmagyi GM. Human ocular torsional position before and after unilateral vestibular neurectomy. *Exp Brain Res* 1991; 85: 218–25.
18. Kanzaki J, Ouchi T. Measurement of ocular counter-torsion reflex with fundoscopic camera in normal subjects and in patients with inner ear lesions. *Arch Otorhinolaryngol* 1978; 218: 191–201.
19. Fetter M, Zee D. Recovery from unilateral labyrinthectomy in rhesus monkeys. *J Neurophys* 1988; 59: 370–93.
20. Herdman SJ. Role of vestibular adaptation in vestibular rehabilitation. *Otolaryngol Head Neck Surg* 1998; 119: 49–54.
21. Halmagyi GM, Curthoys IS, Cremer PD, et al. The human horizontal vestibulo-ocular reflex in response to high-acceleration stimulation before and after unilateral vestibular neurectomy. *Exp Brain Res* 1990; 81: 479–90.

Submitted December 21, 1998; accepted July 15, 1999

Address for correspondence:

A. Schmid-Priscoveanu
Neurology Department
CH-8091 Zürich
Switzerland
Tel: + 41 1 255 5550
Fax: + 41 1 255 4507
E-mail: adriana.schmid@nos.usz.ch