

Neurological evaluation of acute vertical diplopia

■ A. Palla¹, D. Straumann¹

Neurology Department, Zurich University Hospital

Summary

Palla A, Straumann D. Neurological evaluation of acute vertical diplopia. Schweiz Arch Neurol Psychiatr 2002;153:180–4.

Acute vertical diplopia requires an immediate neurological evaluation. The preliminary differential diagnosis is based on a few basic questions, which can be answered by simple clinical tests. The neurologist determines whether the lesion affects the optic, ocular motor, or vestibular system, and confirms that the problem is neural. Otherwise the patient is referred to the ophthalmologist. A thorough neurological assessment then allows concluding whether the lesion is within the central nervous system or peripheral. Photographs of the ocular fundus on both sides help to distinguish between trochlear nerve palsy and ocular tilt reaction or skew torsion. For a finer differential diagnosis, focused MR-imaging is always needed.

The diagnosis of an optic disorder should be considered if the vertical diplopia is clearly monocular. If vertical diplopia is binocular, the neurologist first searches for typical oculomotor (III) or trochlear nerve (IV) palsies. While III-palsy is mostly due to ischaemia (pupil typically spared) or compression (pupil typically affected) of the nerve, IV-palsy is mostly due to head trauma. III- and IV-palsies that go together with retroorbital pain should lead to a careful evaluation for neoplasm, thrombosis, and inflammation of the cavernous sinus.

One can never be absolutely sure whether a typical III- or IV-palsy is due to a problem along the nerve or within the brainstem, except if other signs clearly indicate a lesion within the ipsilateral orbit or cavernous sinus. Thus neuro-imaging should always include MR-imaging of the midbrain to detect

lesions in the nuclei and fascicles of the oculomotor and trochlear nerves. If a suspected III-palsy does not include all of the four corresponding extraocular muscles (superior, inferior, and medial recti; inferior oblique), one should also consider myasthenia gravis, which can mimic any neural extraocular muscle palsy.

Wernicke's disease is always a valid differential diagnosis of binocular vertical diplopia, especially in the presence of pathological nystagmus and ataxia. If binocular vertical diplopia is associated with deficits of multiple cranial nerves, one should consider a demyelinating disease such as Miller-Fisher and Guillain-Barré syndrome.

Skew deviation is a vertical misalignment of the two eyes resulting from disturbance of supranuclear inputs to the ocular motor neurons of the vertical-torsional eye muscles. If skew deviation goes together with ocular torsion towards the lower eye, so-called skew torsion, an imbalance in the vestibular system, mainly a unilateral lesion of "graviceptive" pathways, which combine otolith and vertical semicircular canal signals, is likely. Skew torsion combined with head roll towards the lower eye forms the triad of ocular tilt reaction (OTR).

Consistent with the anatomy of the graviceptive pathways, ipsiversive skew torsion (ipsilateral eye lower, and ipsilateral binocular torsion) and ipsilateral OTR (ipsiversive skew torsion, and ipsilateral head tilt) will occur as a result of unilateral peripheral or pontomedullary lesions below the pontine crossing of the graviceptive pathways. In contrast, a unilateral pontomesencephalic brainstem lesion leads to contraversive skew deviation (contralateral eye lower) and contralateral OTR (contraversive skew deviation, contralateral binocular torsion, and contralateral head tilt). Lesions of cerebellar structures inhibiting the otolith-ocular reflex may also lead to skew torsion.

Correspondence:
Antonella Palla, MD
Neurology Department
University Hospital
CH-8091 Zurich
e-mail: antpalla@access.unizh.ch

¹ The authors are supported by the Swiss National Science Foundation (32-51938.97 SCORE A / 31-63465.00) and the Betty and David Koetser Foundation for Brain Research.

Table 1 Differential diagnosis of vertical diplopia.

	optic	ocular motor	vestibular
outside CNS	refractive media (eye, optic devices)	neural (nn. III, IV)	labyrinthine
		neuro-muscular	neural (n. VIII)
		restrictive	
inside CNS	posterior cortex	midbrain	central vestibular pathways

Distinguishing between IV-palsy and OTR is sometimes difficult. In both conditions the head tilts away from the eye showing hyperdeviation. While the upper eye in IV-palsy is extorted, the upper eye in OTR is intorted. Furthermore, the lower eye in OTR is extorted and both eyes may show a torsional spontaneous nystagmus that beats opposite to the static ocular torsion.

Keywords: neuro-ophthalmology; neuro-otology; strabismus; skew deviation; eye movements; vestibular; skew torsion; ocular tilt reaction

Introduction

Acute vertical double vision is a medical emergency. As, in the majority of cases, vertical diplopia is due to neural damage, the neurologist is often the first specialist who is called to evaluate the patient. In the process of the clinical assessment, the neurologist should try to answer three basic questions concerning the origin of the vertical diplopia: (1) Does the lesion affect the optic, ocular motor, or vestibular system? (2) Is the problem neural? (3) Is there damage within the central nervous system?

Answering these questions leads to an approximate differential diagnosis (table 1), on which the decision for laboratory tests and further evaluations by other specialists, particularly ophthalmologists or otologists, should be based.

Clinical evaluation

If vertical double vision persists during monocular fixation by one of the two eyes, the problem can only be within the optic system. If monocular diplopia disappears when the patient is viewing through a pinhole, an optical aberration within the ocular globe is likely. Otherwise it is necessary to exclude central monocular diplopia.

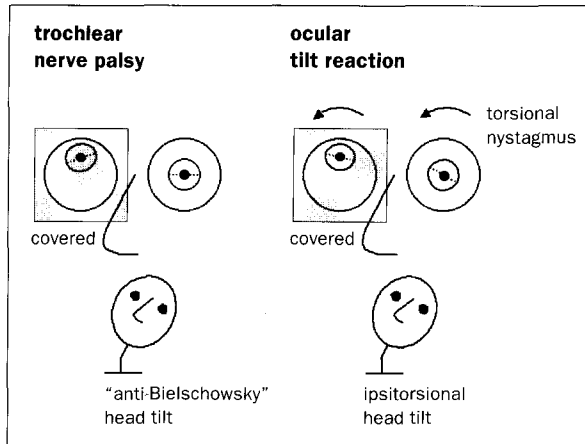
Binocular vertical double vision may only be present in certain gaze directions. The patient is asked to hold his or her eyes in a position that

elicits unambiguous double vision. If one of the two images goes away by covering one eye, the diplopia is binocular. Binocular vertical diplopia is usually associated with vertical misalignment of the two eyes. Thus, the neurologist's next task is to effectively demonstrate this vertical deviation.

Since the vertical fusional reflex can compensate small deviations, especially if the patient is attentive, the alternating cover test should be applied. This test breaks the fusional drive and is performed in the nine cardinal gaze directions. In the presence of a vertical deviation, vertical correcting saccades are elicited upon switching the cover between the eyes. Vertical eye movements of more than 0.5° in the alternating cover test are pathological.

If the amount of vertical deviation notably changes as function of horizontal eye position, a paresis of a vertical rectus (SR = superior rectus; IR = inferior rectus) or an oblique (SO = superior oblique; IO = inferior oblique) muscle is likely. A right eye hyperdeviation that is largest in left gaze is due to ipsilateral SO or contralateral SR palsy; a right eye hyperdeviation that is largest in right gaze is due to ipsilateral IR or contralateral IO palsy [1]. To distinguish between ipsilateral SO and contralateral SR palsy, the head is tilted to either side (Bielschowsky head tilt test). Since the pulling directions of both muscles contain an intorsional component, they are challenged by head roll towards the side of the muscle, thus the vertical-torsional deviation between the two eyes increases when the head is rolled towards the side of the SO or SR palsy. To distinguish between ipsilateral IR and contralateral IO palsy, the head is rolled to the opposite side of the palsy to increase the vertical-torsional deviation, since the pulling directions of these muscles contain an extorsional component. Additional dysfunction of the pupil may indicate involvement of the third cranial nerve and speaks against myasthenia gravis, while ptosis can be found in both conditions. If the presence of extraocular muscle palsy is dubious, one should also look for monocular slowing during saccades along the pulling direction of the muscle.

Figure 1 Similar and dissimilar clinical features of trochlear nerve palsy and ocular tilt reaction.



Clinical ocular motor tests should then focus on detecting lesions of premotor areas in the brainstem and cerebellum (gaze holding network, saccade generator, pursuit system, vestibulo-ocular reflex, vergence system). Such lesions are strong indicators that vertical diplopia most likely is due to a central lesion. The neurologist looks for spontaneous nystagmus (including downbeat nystagmus), gaze-evoked nystagmus, saccadic dysfunctions (metrics, dynamics, oscillations), gaze palsies, and smooth pursuit deficits. These tests should be performed in the horizontal and vertical directions, while vergence deficits and internuclear ophthalmoplegia are usually seen in the horizontal plane. A one-sided peripheral vestibular deficit, which can also lead to transient vertical diplopia, is best revealed by the Halmagyi-Curthoys head impulse test [2]. Abnormal head posture in the roll plane indicates a vestibular or ocular motor disorder. Fundoscopy can help to distinguish between the two possibilities (fig. 1), but for precise results one should obtain fundusphotographs of both eyes.

A thorough neurological examination of patients with acute vertical diplopia is indispensable and should concentrate on identifying lesions in the brainstem and cerebellum.

Differential diagnosis

Optic disorders

The diagnosis of an optic disorder should be considered if the vertical diplopia is clearly monocular. A positive pinhole test points towards a peripheral mechanism, i.e. an optical aberration within the refractive media of the eye [3]. In that case, the patient should be referred to the ophthalmologist. If, however, monocular vertical diplopia persists

when the patient is viewing through a pinhole, the differential diagnosis includes the rare possibility of a central optic disorder, most likely a posterior cortical dysfunction. The neurologist then should not hesitate to order brain imaging, even in the absence of other neurological signs and symptoms. "Psychogenic vertical diplopia" should not be on the list, until all tests are negative.

Ocular motor disorders

If vertical diplopia is binocular [4–6], the neurologist first searches for typical oculomotor (III) or trochlear nerve (IV) palsies. While III-palsy is mostly due to ischaemia (pupil typically spared) or compression (pupil typically affected) of the nerve, IV-palsy is mostly due to head trauma. If the trauma was rather weak, one should always consider the possibility of decompensating congenital trochlear nerve palsy. In this case, old photographic portraits would show a head tilt opposite to the side of the trochlear nerve palsy. Brown's syndrome (limited movement of the SO tendon through the trochlear pulley) can mimic a IV-palsy. The forced duction test, which should be left to the ophthalmologist, is diagnostic for this syndrome. III- and IV-palsies that go together with retro-orbital pain should lead to a careful evaluation for neoplasm, thrombosis, and inflammation (Tolosa-Hunt syndrome) of the cavernous sinus.

Distinguishing between IV-palsy and ocular tilt reaction is sometimes difficult. In both conditions the head tilts away from the eye showing hyperdeviation (fig. 1). While the upper eye in IV-palsy is extorted, the upper eye in ocular tilt reaction is intorted. Furthermore, the lower eye in ocular tilt reaction is extorted and both eyes may show a torsional spontaneous nystagmus that beats opposite to the static ocular torsion [7].

One can never be absolutely sure whether a typical III- or IV-palsy is due to a problem along the nerve or within the brainstem, except if other signs clearly indicate a lesion within the ipsilateral orbit or cavernous sinus. Thus neuro-imaging should always include MR-images of the midbrain to detect lesions in the nuclei and fascicles of the oculomotor and trochlear nerves. If a suspected III-palsy does not include all of the four corresponding extraocular muscles (superior, inferior, and medial recti; inferior oblique), one should also consider myasthenia gravis, which can mimic any neural extraocular muscle palsy. Myasthenia gravis without ptosis, however, is rare. A typical III-palsy that involves the pupil cannot be due to myasthenia gravis.

Isolated lesions of the oculomotor nucleus are rare. They should be considered if ptosis (levator palpebrae neurons originate from the unpaired central caudal nucleus) and SR-palsy (SR-neurons cross to the other side) are present on the contralateral side. Fascicular III-lesions are usually combined with other signs, such as contralateral hemiparesis (cerebral peduncle: Weber's syndrome), contralateral tremor (red nucleus: Benedikt's syndrome), or ipsilateral ataxia (superior cerebellar peduncle: Nothnagel's syndrome). **Lesions of the nucleus or fascicle of the trochlear nerve result in contralateral IV-palsy.** More often than not, they are associated with other signs such as ipsilateral internuclear ophthalmoplegia (medial longitudinal fascicle), ipsilateral Horner's syndrome (descending sympathetic fibres in the periaqueductal gray), or contralateral afferent defect of the pupil (pretectal fibres).

Wernicke's disease is always a valid differential diagnosis of binocular vertical diplopia, especially in the presence of pathological nystagmus and ataxia. If binocular vertical diplopia is associated with deficits of multiple cranial nerves, one should consider a demyelinating disease such as Miller-Fisher and Guillain-Barré syndrome.

Restrictive processes can also lead to binocular vertical diplopia, most of all Graves' disease, which is usually identified by other signs such as lid retraction, lid lag, and proptosis. If there is any suspicion of a restrictive orbital process, the patient should be referred to the ophthalmologist.

Vestibular disorders

Skew deviation is a vertical misalignment of the two eyes resulting from disturbance of supranuclear inputs to the ocular motor neurons of the vertical-torsional eye muscles. If skew deviation goes together with ocular torsion towards the lower eye, so-called skew torsion, an imbalance in the vestibular system, mainly a unilateral lesion of "graviceptive" pathways, which combine otolith and vertical semicircular canal signals, is likely [7]. Skew torsion combined with head roll towards the lower eye forms the triad of ocular tilt reaction.

To understand skew torsion or ocular tilt reaction, one must consider certain properties of the otolith-ocular reflex. Normally, rolling the head from the upright position leads to binocular torsion in the opposite direction (ocular counterroll) and minor skew deviation (extorting eye lower) to partially align the retina of both eyes with the horizon. Thus, skew torsion and ocular tilt reaction represent a fundamental pattern of eye-head synergy

upon utricular and vertical semicircular canal inputs [8]. Hence, peripheral or central lesions disrupting these graviceptive pathways result in skew torsion or ocular tilt reaction.

A topologic diagnosis of skew torsion and ocular tilt reaction requires exact knowledge of the anatomy of the otolith-ocular reflex pathways. The vestibular nerve, containing axons from the otolith and semicircular canal organs, enters the medulla near the caudal end of the pons. In the vestibular nuclei, which are located below the floor of the fourth ventricle, otolith and vertical semicircular canals signals converge to form the graviceptive pathways. These pathways cross to the other side of the brainstem approximately in the middle of the pons and further ascend in the medial longitudinal fascicle to the ocular motor nuclei (nuclei III and IV) and the premotor gaze centres in the rostral midbrain. From there further connections reach multiple cortical areas through thalamic projections.

Consistent with the anatomy of the graviceptive pathways, ipsiversive skew torsion (ipsilateral eye lower, and ipsilateral binocular torsion) and ipsilateral ocular tilt reaction (ipsiversive skew torsion, and ipsilateral head tilt) will occur as a result of unilateral peripheral or pontomedullary lesions below the pontine crossing of the graviceptive pathways. In contrast, a unilateral pontomesencephalic brainstem lesion leads to contraversive skew deviation (contralateral eye lower) and contralateral ocular tilt reaction (contraversive skew deviation, contralateral binocular torsion, and contralateral head tilt). Lesions of cerebellar structures inhibiting the otolith-ocular reflex may also lead to skew torsion [9].

Common causes of ocular tilt reaction are brainstem ischaemia, especially Wallenberg's syndrome, and unilateral paramedian thalamic infarction with involvement of the midbrain. Thalamic lesions without damage to the midbrain do not lead to skew torsion or ocular tilt reaction. Since both graviceptive pathways and internuclear connection between ocular motor nuclei travel along the medial longitudinal fascicle, skew torsion due to pontomesencephalic lesions is frequently associated with internuclear ophthalmoplegia.

Vertical diplopia due to peripheral or central vestibular lesions always includes binocular torsion towards the lower eye. Hence the direction of fundoscopic cyclorotation distinguishes between hypertropia due to trochlear palsy (excyclorotation) and hypertropia due to skew torsion (incyclorotation) (fig. 1). Vertical deviations in both trochlear nerve palsy and skew torsion may be concomitant or non concomitant, thus concomitance is

not a criterion to discriminate between the two conditions. Likewise, additional signs of midbrain lesions do not speak in favour of skew torsion, since trochlear nerve palsy can also occur as a result of a lesion within the brainstem.

Conclusion

The complete differential diagnosis of acute vertical double vision includes fifty or more syndromes or diseases. This should not prevent the neurologist from first distinguishing between optic, ocular motor, and vestibular pathological mechanisms and answering the most basic topologic questions. The finer differential diagnosis is usually based on neuro-imaging, which can only be successful if the neurologist has a clear idea of the neural structures that are affected by the disease.

Acknowledgment: We would like to thank Dr Christopher Bockisch for the proof-reading of the manuscript.

References

- 1 Parks MM. Isolated cyclovertical muscle palsy. *Arch Ophthalmol* 1958;60:1027–35.
- 2 Halmagyi GM, Curthoys IS. A clinical sign of canal paresis. *Arch Neurol* 1988;45:737–9.
- 3 Burde RM, Savino PJ, Trobe JD. Diplopia and Similar Sensory Experiences. *Clinical Decisions in Neuro-ophthalmology*. 2nd ed. St. Louis: Mosby; 1992. p. 224–38.
- 4 Spector RH. Vertical diplopia. *Surv Ophthalmol* 1993;38:31–62.
- 5 Brazis PW, Lee AG. Binocular vertical diplopia. *Mayo Clin Proc* 1998;73:55–66.
- 6 Bennett JL, Pelak VS. Palsies of the third, fourth, and sixth cranial nerves. *Ophthalmol Clin North Am* 2001;14:169–85, ix.
- 7 Brandt T, Dieterich M. Vestibular syndromes in the roll plane: topographic diagnosis from brainstem to cortex. *Ann Neurol* 1994;36:337–47.
- 8 Leigh RJ, Zee DS. *The neurology of eye movements*. 3rd ed. New York: Oxford University Press; 1999.
- 9 Mossman S, Halmagyi GM. Partial ocular tilt reaction due to unilateral cerebellar lesion. *Neurology* 1997;49:491–3.